



Radiographs are not sufficient for evaluation of component fit in subtle knee pain after total knee arthroplasty

Mehmet Emin Simsek¹ · Safa Gursoy² · Mustafa Akkaya² · M. I. Safa Kapicioglu³ · Murat Bozkurt³ 

Received: 1 December 2019 / Accepted: 13 March 2020 / Published online: 27 March 2020
© European Society of Sports Traumatology, Knee Surgery, Arthroscopy (ESSKA) 2020

Abstract

Purpose To determine the component fit by radiography or computed tomography after total knee arthroplasty and the relation of imaging with clinical examination of residual knee pain.

Methods The study was conducted in 172 patients with residual knee pain after total knee arthroplasty. The patients were examined to determine whether they experienced pain upon palpation at nine regions surrounding the tibial and femoral components, and the results were noted. The Knee Society Clinical Rating System and The Western Ontario and McMaster Universities Arthritis Index pain scale score forms were completed for all patients. Radiologic evaluation was performed using computed tomography and anteroposterior, lateral, and oblique radiographs to determine component overhang/underhang status at these nine regions. Overhang, underhang, and cortical fit groups were created based on the position of the component at the bone margin. A statistical relationship was sought between the clinical scores and the values measured to determine which imaging method showed the best correlation with clinical scores. Consistency of CT and Rx measurements was compared using the McNemar–Bowker test. Comparisons between groups were made using Student’s t test for normally distributed data, and the Mann–Whitney U test.

Results Computed tomography and radiographic measurements were similar in the medial, anterior, and lateral tibial regions. However, no similarities were observed in the anteromedial, anterolateral, posteromedial, and posterolateral tibial regions, and in the distal-medial and distal-lateral aspects of the femur. Statistical relationships among decreased clinical scores, pain with palpation, and the presence of overhang/underhang were only observed in the medial tibial region for imaging using radiography. A statistically significant relationship was observed in the medial, posteromedial, and posterolateral tibial regions, and in the distal-medial region of the femur for imaging based on computed tomography.

Conclusions Radiography could only aid in assessing the component fit in the anteromedial, medial, and lateral regions of the tibia in patients with residual knee pain following knee arthroplasty, but it was not sufficient in comparison with computed tomography in six other regions.

Level of evidence Prospective study, level of evidence II.

Keywords Total knee arthroplasty · Tibial baseplate · Residual knee pain · Clinical outcome · Radiographs · Computed tomography

✉ Murat Bozkurt
nmbozkurt@gmail.com

Mehmet Emin Simsek
mehmeteminsimsek@gmail.com

Safa Gursoy
safagursoy@yahoo.com

Mustafa Akkaya
makkaya@outlook.com

M. I. Safa Kapicioglu
safakapicioglu@yok.gov.tr

¹ Department of Orthopedics and Traumatology, Lokman Hekim University, 06084 Ankara, Turkey

² Department of Orthopedics and Traumatology, Ankara Yenimahalle Training and Research Hospital, Yildirim Beyazit University, 06100 Ankara, Turkey

³ Department of Orthopedics and Traumatology, Yildirim Beyazit University, 06100 Ankara, Turkey

Introduction

According to the long-term outcomes following knee arthroplasty (TKA), survival after 15 years was reported to be > 90% [7, 11]. Recent studies have shown that accurate placement and optimal sizing of femoral and tibial components are closely associated with rapid rehabilitation and reduction of pain in the postoperative period, as well as longevity of the TKA with good functional outcomes [4, 11]. However, despite these favorable outcomes, residual pain after TKA is still commonly encountered and is an important cause of patient dissatisfaction. Malposition and overhang of tibial and femoral components cause soft tissue impingement, which leads to instability and stiffness in the knee joint, resulting in chronic pain and decreased quality of life [1, 13]. The presence of implant overhang or underhang (O/U) from bone borders is generally not detectable during conventional radiographic (Rx) imaging because the bone and implant can be superimposed owing to their three-dimensional structure, which may affect the diagnosis and treatment [4, 11, 13]. Rx is not sufficient to evaluate the O/U component position in patients attending the outpatient clinic with subtle pain TKA, and this may lead to misdiagnosis. Computed tomography (CT) provides more comprehensive multiplanar images, and this may allow a more accurate assessment of O/U. Thus, this study aimed to elucidate whether Rx is sufficient, and whether CT is superior to Rx, in determining the presence of O/U surrounding the TKA components. In addition, the study aimed to evaluate the correlation of these two imaging methods with detailed clinical examination of patients with residual knee pain after TKA.

Methods

Patient selection

Informed consent forms were completed by the patients prior to their participation. TKA was performed by the same surgical team on all patients using a NexGen® LPS-Flex Fixed Bearing Total Knee (Zimmer-Biomet, Warsaw, ABD). Tourniquets and surgical drains were used in all patients. A standard postoperative rehabilitation program was conducted by the same physiotherapists.

Inclusion criteria

Patients aged between 50–75 years in whom unilateral TKA was indicated between 2010 and 2015 were assessed for inclusion in the study. Patients were followed-up

postoperatively for at least 3 years at 6-month intervals. Those who had residual knee pain in at least one of nine palpation regions that could not be alleviated, despite 3 months of medical and physical therapy in the outpatient clinic, were included in the study. Palpation regions (r) were defined as the distal-medial femur (FM), distal-lateral femur (FL), tibia anterior (TA), tibia anterolateral (TAL), tibia antero-medial (TAM), tibia medial (TM), tibia lateral (TL), tibia posteromedial (TPM) and tibia posterolateral (TPL) (Fig. 1). Patients were included in the study provided that they did not have a TKA performed on the other knee, had a Body Mass Index < 35, and an American Society of Anesthesiologists Physical Status Classification (ASA) score of 1–3. The Knee Society Clinical Rating System (KSS) [9] and The Western Ontario and McMaster Universities Arthritis Index pain scale (WOMAC-P) [3] were completed during postoperative follow-ups.

Exclusion criteria

Those patients who could not complete the KSS and WOMAC-P scores were excluded.

Other exclusion criteria were: TKA of the other knee; poor wound healing after surgery; periprosthetic infection or low-grade infection according to laboratory and clinical results; a disease that manifests with peripheral neuropathy or neuropathy (e.g., Diabetes mellitus); instability or mid-flexion instability; less than 90% tibial coverage without rotational malalignment in the tibial and femoral component and without axial malalignment detected by CT; crepitation, mal-tracking, and patellar clunk; periprosthetic fracture; more than 3° of varus or valgus malalignment in the components; osteolysis; septic or aseptic loosening of components; and patients who could not mobilize themselves (Fig. 2).

Measurements

The same group of physiotherapists performed all measurements, and data were recorded in the patient registry. KSS and WOMAC-P scores of all patients were then compared between the overhang, underhang, and cortical fit groups that were separately created for each region examined clinically. The WOMAC-P score consists of five items, each scored on a five-point scale (0–4). Thus, pain scores can vary from 0 to 20 with higher scores representing greater levels of pain. The KSS score grading is as follows: 100–80 excellent; 79–70 good; 69–60 fair; and < 60 poor. In assessing pain status in the nine regions investigated in the study, the examination was completed twice by three physiotherapist observers. The degree of measurement reliability was assessed using intraclass correlation coefficients. The 95% confidence intervals of intraclass correlation coefficients were 0.936–0.972. Patients were divided into two subgroups,

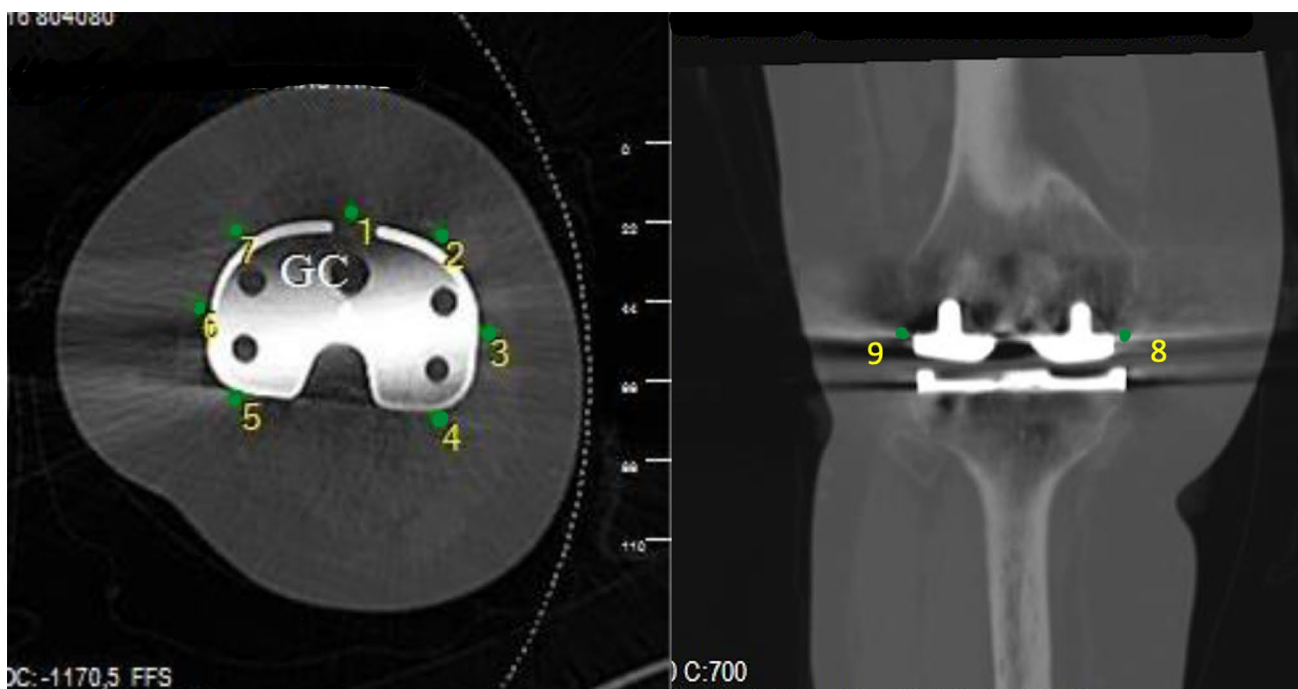
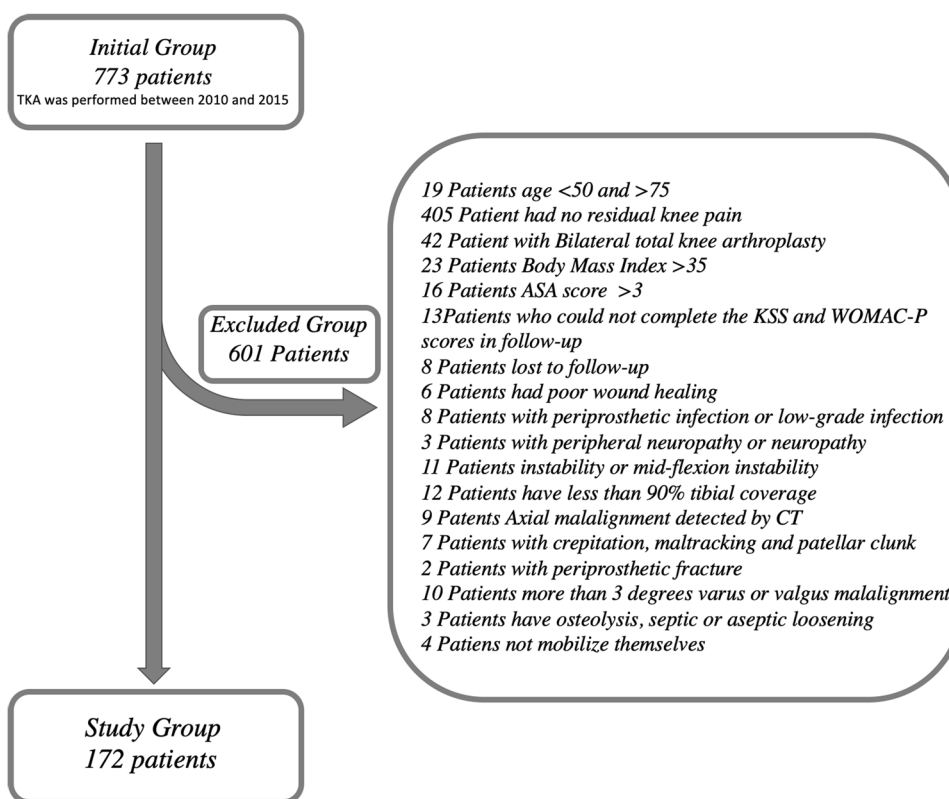


Fig. 1 Measurement regions around the tibial and femoral components. 1, tibia anterior region; 2, tibia anterolateral region; 3, tibia lateral region; 4, tibia posterolateral region; 5, tibia posteromedial

region; 6, tibia medial region; 7, tibia anteromedial region; 8, Femur medial region; and 9, Femur lateral region

Fig. 2 Flowchart of the excluded patients



“pain free” (PF) and “with pain” (WP) depending on the reports of pain at nine measurement regions on examination (Figs. 3, 4). The localization of components with respect to the bone margins at these nine regions around the tibial and femoral components was then compared between PF and WP groups.

Radiologic evaluation

Rx was performed with patients in the standing position to obtain full anteroposterior, full lateral side, and two-directional oblique views. An anterolateral to posteromedial oblique Rx was taken with 45° internal rotation of the leg, while an anteromedial to posterolateral Rx was made with 45° external rotation of the leg. CT scans were achieved with 0.6 mm slice thickness using metal artifact reduction software (256-slice multidetector scanner; Siemens®, Erlangen, Germany) [2, 10]. Standardization, magnification, and measurement of the obtained images were conducted

automatically with Leonardo Dr/Dsa Va30a software (Siemens®, Erlangen, Germany), and each patient’s Rx and CT images were measured using digital rulers with precision of 1/10 mm. Double-blind CT and Rx measurements for each patient were conducted at nine different regions determined by four orthopedists (MB, MA, SG, MES). The degree of measurement reliability was assessed using intraclass correlation coefficients (ICC). Interobserver ICC was 0.82, and intraobserver ICC was 0.86 For CT measurements. Interobserver ICC was 0.84, and intraobserver ICC was 0.90 for Rx measurements. Among all measurements, the highest margin of error was 0.7 mm for CT and 0.9 mm for Rx. The localization of component edges with respect to the bone margins was assessed in nine regions for each patient using the two radiological methods separately for each patient. The component localization in each region was classified into three groups. The margin of error was nearly 1 mm, and therefore overhang of more than 1 mm from the bone border was classified as an overhang (O), underhang more

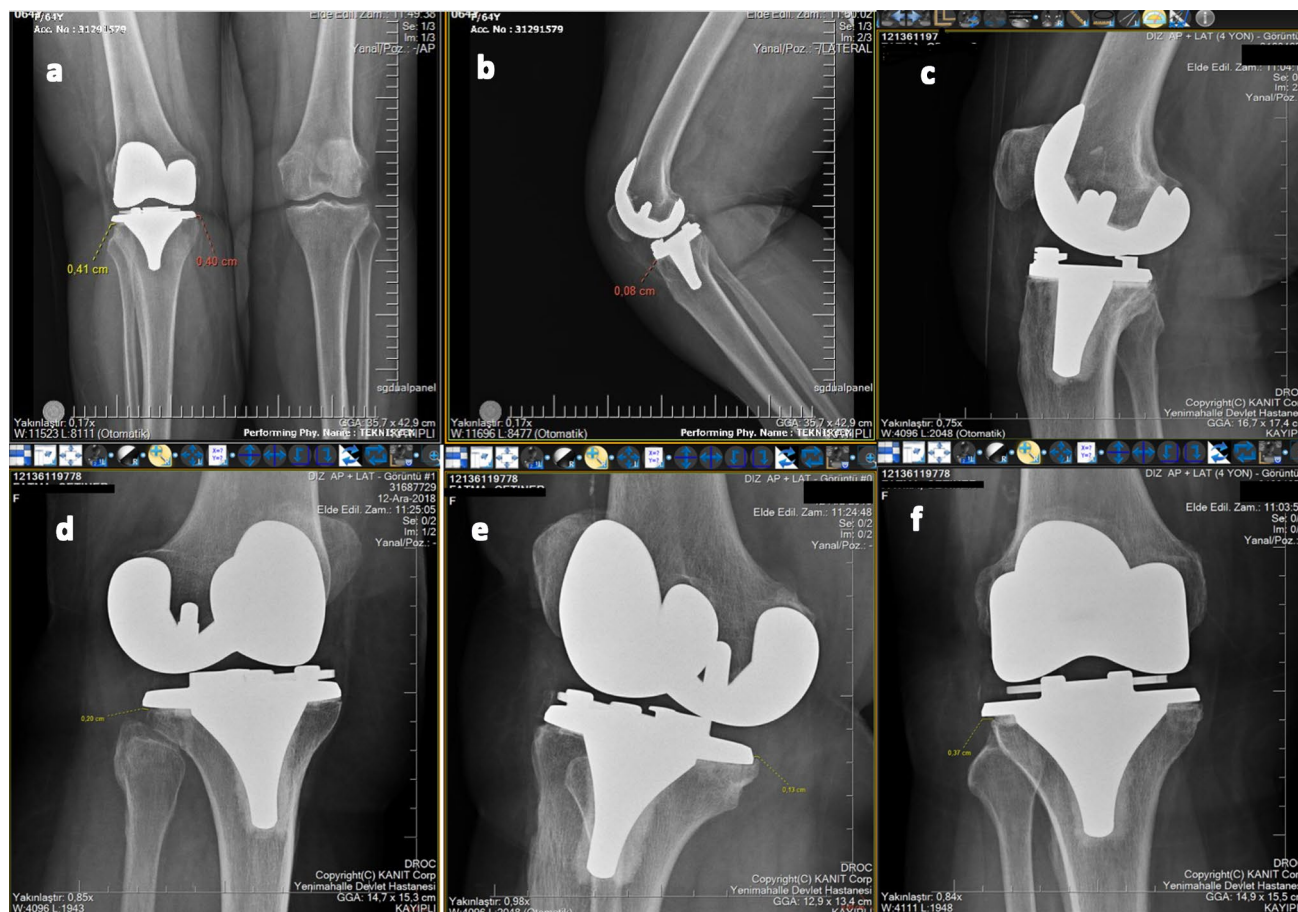


Fig. 3 Measurement of component position with conventional radiographs (Rx) in nine regions. View of the Lateral overhang and medial underhang of tibial components with anteroposterior Rx (a); View of the anterior underhang of tibial components (b); and cortical fit placement of the tibial component (c); with lateral side Rx; view of

the posterolateral overhang of the tibial component with 45° internal oblique Rx (d) view of the posteromedial underhang of the tibial component with 45° external oblique Rx (e); and overhang or underhang was unable to measure distal-medial and lateral border of the femur because of the radiopaque femoral component (f)

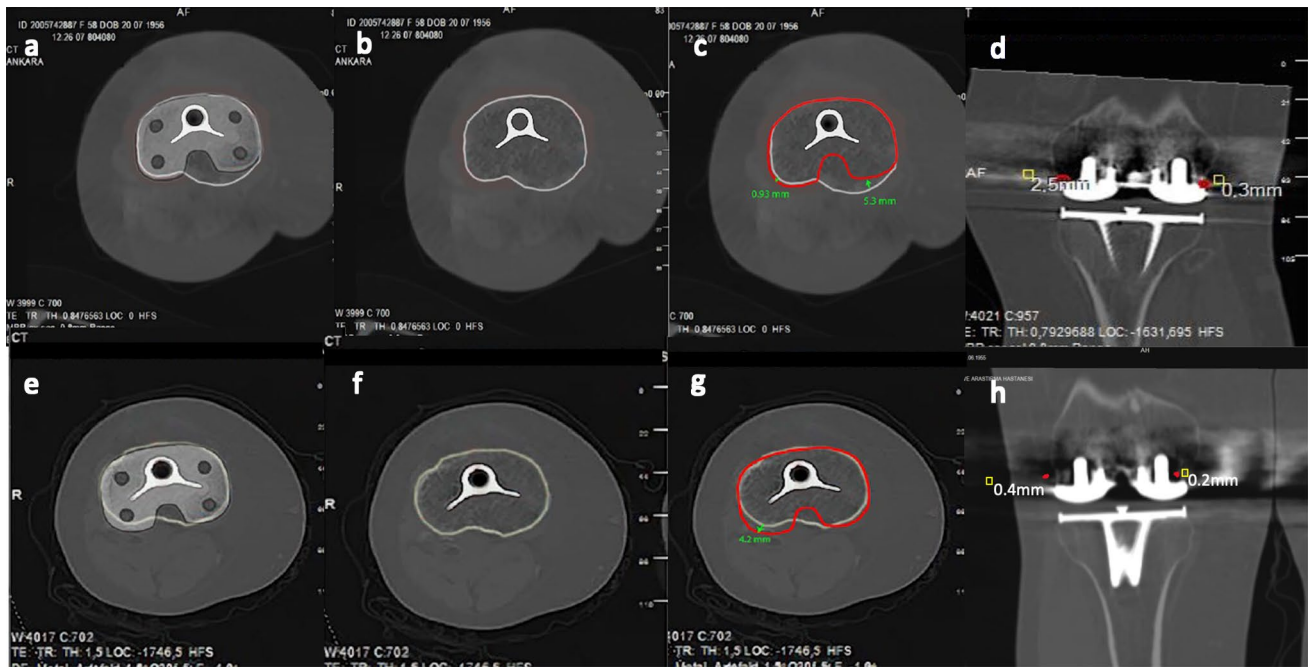


Fig. 4 Measurement of component position as observed computed tomography in nine regions. Patient 1: placement of the tibial component on the tibial plateau (a), the border of tibia plateau (b), overhang in posterolateral region and underhang in posteromedial region of the tibial component (c), overhang of the femoral component in distal-

medial and distal-lateral border of the femur (d). Patient 2: placement of the tibial component on the tibial plateau (e), the border of tibia plateau (f), overhang in posterolateral region of the tibial component (g), underhang of the femoral component in distal-medial, and distal-lateral border of the femur (d)-

than 1 mm from the bone border was classified as an underhang (U), and placement within these values was classified as cortical fit (C). Considering the nine measurement regions in each patient, one region may have overhang and another region may have underhang at the same time. Moreover, overhang detected using CT may be included in another group when measured using Rx (e.g., underhang or cortical fit) (Figs. 3, 4).

Approval of the Institutional Review Board (IRB) of Yıldırım Beyazıt University (IRB File No. 2018–2–061) was obtained for the data collection method and research design of this prospective study.

Statistical analysis

Statistical analysis was performed using the statistical software package SPSS (Version 25.0, SPSS Inc., Chicago, IL, USA). For each continuous variable, normality was checked by Kolmogorov–Smirnov and Shapiro–Wilk tests, and by histograms. All numerical data are expressed as mean (\pm Standard Deviation), median values (Minimum–Maximum), or as proportions. Comparisons between groups were made using Student’s *t*-test for normally distributed data, and the Mann–Whitney *U* test was used for the non-normally distributed data. Consistency of CT and Rx measurements was compared using the McNemar–Bowker test.

A *p* value < 0.05 was defined as statistically significant. A post hoc power analysis for detecting differences in the Rx and CT measurements between the two groups was conducted. The statistical software G*Power (Erdfeiler, Faul, Germany, 2014) was used for power analyses. Based on the results of the ANOVA evaluating, an effect size of 0.88 ($\alpha = 0.05$), and a sample size of 164 patients, a power of 0.88 was calculated.

Results

Of the 773 patients in whom knee arthroplasty was indicated, a total of 172 patients, who complied with the inclusion and exclusion criteria, were included in the study. There were 75 males (43.6%), and 97 females (56.4%). Age, body mass index, postoperative (post-op) months, and post-op KSS and WOMAC-P scores were similar for both sexes (n.s.). The distribution of the frequency of pain in the nine regions examined is shown in Table 1. Patients who expressed pain in the TMr, TPMr, TPLr, and FMr had lower KSS, and higher WOMAC-P scores, than the patients who did not have any pain in these regions (Table 1).

For CT measurements, the KSS score was lower and the WOMAC-P score was higher in those assessed as U group when compared with C group in the TMr and TPMr, and

Table 1 For all 172 patients, whether the presence of pain by examination in 9 regions around the knee is shown in the table

Palpation locations	Pain (+) n (%)	Pain (–) n (%)
TAr	11 (6.4%)	161 (93.6%)
TMr	47 (27.3%)	125 (72.7%)
TLr	14 (8.1%)	158 (91.9%)
TAMr	8 (4.6%)	164 (95.4%)
TALr	5 (2.9%)	167 (97.1%)
TPMr	53 (30.8%)	119 (69.2%)
TPLr	45 (26.2%)	127 (73.8%)
FMr	22 (12.8%)	150 (87.2%)
FLr	28 (16.3%)	144 (83.7%)

TAr Tibia anterior region, TMr Tibia medial region, TLr Tibia lateral region, TAMr Tibia anteromedial region, TALr Tibia anterolateral region, TPMr Tibia posteromedial region, TPLr Tibia posterolateral region, FMr femur distal-medial region, FLr femur distal-lateral region

was lower in those assessed as O group in the TPLr and FMr. In the WP group, the underhang at TMr was measured as -3.7 ± 0.6 mm, while at TPMr it was -6.8 ± 1.9 mm; at TPLr the overhang was 5.3 ± 2.1 mm, while at FMr it was 4.2 ± 1.1 mm.

For Rx measurements, the KSS score was lower and the WOMAC-P score was higher in the group that had underhang in the TMr compared to the group that had cortical fit. In the WP group, at the TMr -3.0 ± 1.4 mm underhang was observed (Table 2 and Fig. 5).

The overhang in the CT measurements at FMr and FLr was observed as cortical fit or underhang with Rx measurements. CT and Rx measurements were similar for the TAr, TMr, and TLr (Fig. 5).

Discussion

The most important finding of this study was that Rx could only help assess component O/U in the TAr, TMr, and TLr in patients with residual knee pain following TKA, but it was not sufficient in comparison with CT in other regions. In most patients seen at the clinic, residual knee pain is evaluated only by anteroposterior (AP) and mediolateral (ML) Rxs, which are the primary tests after a physical examination. A correlation between the data obtained from Rx and patient clinical outcomes cannot be established because Rx cannot provide a distinction between the component and bone borders. Therefore, it is usually not possible to determine the etiology of knee pain with such tests [12, 14]. This may be because the distal femur and proximal tibia do not have anatomical structures with smooth margins, and each patient has different morphometric characteristics. Rx provides two-dimensional images, and the metal implants used in TKA or the bones are often superimposed in oblique Rx, preventing a clear view of the bone borders [8, 14, 17]. In CT scans, small amounts of component overhang can be ignored or missed, since loosening, coverage, and rotational alignment are generally taken into account in these scans [6, 8]. This study was focused on investigating the extent to which it was possible to detect component overhang that could cause soft tissue impingement using Rx and CT, and which diagnostic method was more reflective of clinical scores. There are no studies in the literature that evaluate the effect of overhang and underhang in all the regions surrounding the component on clinical scales, along with the relationship between overhang, underhang, and pain. A few studies suggest that anteroposterior oversizing of the tibial component may cause pain [15, 16].

Table 2 The relationship between pain and the clinical scores variables for nine region

n = 172	KSS			WOMAC-P		
	Pain free group	With pain group	p value	Pain free group	With pain group	p value
	Mean \pm SD (Min; Max)	Mean \pm SD (Min; Max)		Mean \pm SD (Min; Max)	Mean \pm SS (Min; Max)	
TAr	85.9 \pm 5.2 (39.0; 92.0)	86.6 \pm 6.7 (42.0; 94.0)	n.s.	4.3 \pm 1.9 (3.0; 12.0)	3.8 \pm 2.4 (0.0; 8.0)	n.s.
TMr	82.8 \pm 4.5 (41.0; 90.0)	87.4 \pm 6.0 (44.0; 94.0)	< 0.05	5.2 \pm 2.3 (3.0; 12.0)	2.1 \pm 1.0 (0.0; 10.0)	< 0.05
TLr	86.9 \pm 5.0 (48.0; 94.0)	87.1 \pm 3.3 (43.0; 90.0)	n.s.	3.0 \pm 2.2 (0.0; 12.0)	3.2 \pm 1.1 (0.0; 11.0)	n.s.
TAMr	87.2 \pm 4.1 (42.0; 92.0)	87.6 \pm 3.8 (39.0; 94.0)	n.s.	3.2 \pm 1.9 (0.0; 12.0)	2.9 \pm 1.4 (1.0; 10.0)	n.s.
TALr	86.8 \pm 5.4 (40.0; 94.0)	88.0 \pm 4.2 (54.0; 94.0)	n.s.	3.4 \pm 2.8 (0.0; 9.0)	3.1 \pm 2.1 (0.0; .0)	n.s.
TPMr	78.6 \pm 4.1 (39.0; 88.0)	88.8 \pm 5.0 (52.0; 94.0)	< 0.05	7.2 \pm 2.4 (5.0; 12.0)	2.1 \pm 1.9 (0.0; 6.0)	< 0.05
TPLr	79.1 \pm 3.8 (43.0; 86.0)	89.1 \pm 3.2 (58.0; 94.0)	< 0.05	6.4 \pm 3.7 (3.0; 12.0)	3.3 \pm 1.1 (0.0; 11.0)	< 0.05
FMr	81.3 \pm 2.7 (46.0; 88.0)	87.5 \pm 3.5 (39.0; 94.0)	< 0.05	4.7 \pm 2.1 (0.0; 12.0)	2.6 \pm 1.9 (0.0; 8.0)	< 0.05
FLr	88.6 \pm 4.4 (39.0; 92.0)	89.3 \pm 2.9 (39.0; 94.0)	n.s.	3.8 \pm 1.63 (0.0; 12.0)	3.2 \pm 1.8 (0.0; 10.0)	n.s.

TAr Tibia anterior region, TMr Tibia medial region, TLr Tibia lateral region, TAMr Tibia anteromedial region, TALr Tibia anterolateral region, TPMr Tibia posteromedial region, TPLr Tibia posterolateral region, FMr femur distal-medial region, FLr femur distal-lateral region, n.s. non-significant

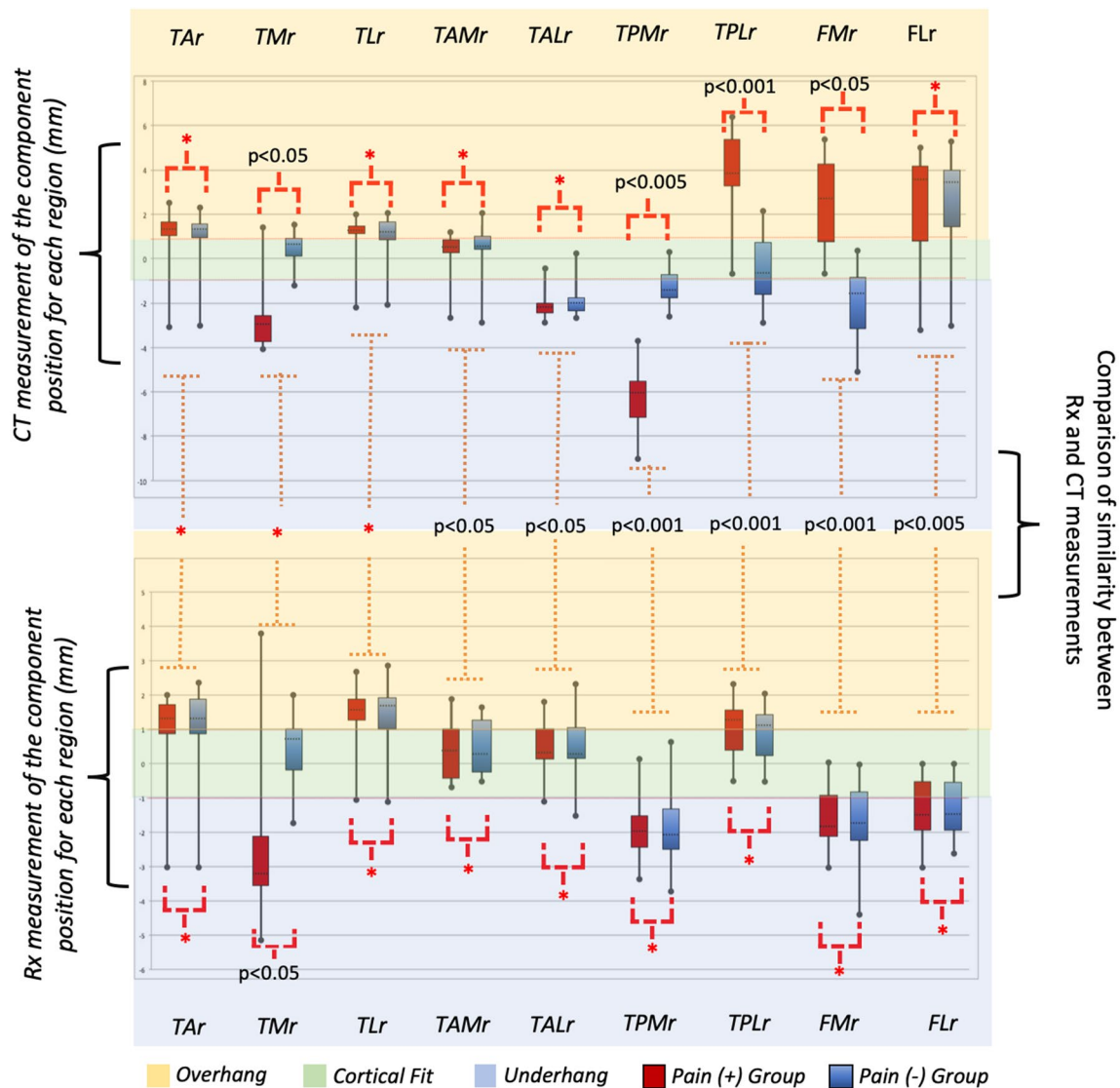


Fig. 5 The relationship between the amount of overhang/underhang and pain in the nine regions with CT and Rx measurements. Evaluation of the similarity between CT and Rx measurements in nine regions. *TAr* tibia anterior region, *TMr* tibia medial region, *Tlr* tibia

lateral region, *TAMr* tibia anteromedial region, *TALr* tibia anterolateral region, *TPMr* tibia posteromedial region, *TPLr* tibia posterolateral region, *FMr* femur distal-medial region, *FLr* femur distal-lateral region. *Non-significant (n.s.)

According to this study, clinical scores exhibited a negative change as a result of overhang in the TPLr and FMr, and underhang in the TMr and TPMr, and this was associated with pain in those assessed by CT measurements. However, Rx revealed underhang only in the TMr, which was similar clinically as when CT was used, and was associated with pain. Besides overhang, in cases of underhang, especially in the TPMr and TMr, an undersized implant can be harmful in theory, as it would leave an uncovered cancellous bone surface, wherein the friction between soft tissues and bone ridges could lead to pain. Rx was found to provide insufficient evaluation, due to bone superimposition in the oblique Rxs. Bonnin et al. [5] conducted a study to determine the

mechanism and extent of popliteus impingement before and after TKA, and to evaluate the effect of implant sizing. According to the results of that study, oversize at TPLr can cause residual knee pain. These findings suggest that popliteus impingements could play a role in residual pain and stiffness following TKA. In a study by Mahoney et al., the medial and lateral overhang of the femoral component was noted to investigate the effects on postoperative clinical outcomes. A femoral component overhang of > 3 mm in at least one zone was associated with a twofold increased risk in significant knee pain, at 2 years after surgery [12].

This study has some limitations. Firstly, pain that occurs with palpation of the soft tissue at the implant margins can

be linked to inflammatory changes. Secondly, the factors causing low outcome scores in cases other than those with ideal rotation (cases with implants in internal or external rotation) were not differentiated regarding whether these low outcome scores were due to rotational errors or overhang. Finally, palpation of anatomical landmarks can be difficult especially in obese patients, and identification of the regions evaluated in this study by palpation does not seem to be an ideal method.

The results of this study should be carefully considered when assessing residual knee pain after TKA. Although Rx may be preferred for the initial evaluation of residual knee pain at tibia anteromedial, tibia medial, and tibia lateral regions, CT should be used to evaluate overhangs and underhangs at the other six regions around the components. Rx may be inadequate, and CT evaluation is recommended in these patients.

Conclusions

The results of this study have shown that overhang in the posterolateral tibial region and distal-medial region of the femur, and underhang in the posteromedial and medial tibial region, have a negative impact on clinical outcomes after TKA and, therefore, pose a danger to the success of TKA. Furthermore, it was seen that as a standard technique, Rx was inadequate at detecting component alignment errors and explaining the clinical examination results. This study recommends assessing component position with CT to evaluate the implant position in patients with residual pain.

Funding This research did not receive any specific grants.

Compliance with ethical standards

Conflict of interest The authors have no relevant conflicts of interest to declare.

Ethical approval The study was approved by the Human Ethics Committee at Yıldırım Beyazıt University.

Informed consent Written informed consent was obtained from all the patients.

References

- Anderson JG, Wixson RL, Tsai D, Stulberg SD, Chang RW (1996) Functional outcome and patient satisfaction in total knee patients over the age of 75. *J Arthroplasty* 11:831–840
- Bessette MC, Amsdell SL, Giordano BD, Kates SL (2017) The utility of postoperative radiographs 2 years after primary total knee arthroplasty. *J Arthroplasty* 32:106–109
- Bilbao A, Quintana JM, Escobar A, Las Hayas C, Orive M (2011) Validation of a proposed WOMAC short form for patients with hip osteoarthritis. *Health Qual Life Outcomes* 9:75
- Bonnin M, Deschamps G, Neyret P, Chambat P (2000) Revision in non-infected total knee arthroplasty: an analysis of 69 consecutive cases. *Rev Chir Orthop Reparatrice Appar Mot* 86:694–706
- Bonnin MP, de Kok A, Verstraete M, Van Hoof T, Van Der Straten C, Saffarini M et al (2017) Popliteus impingement after TKA may occur with well-sized prostheses. *Knee Surg Sports Traumatol Arthrosc* 25:1720–1730
- Chau R, Gulati A, Pandit H, Beard DJ, Price AJ, Dodd CA et al (2009) Tibial component overhang following unicompartmental knee replacement—does it matter? *Knee* 16:310–313
- Diduch DR, Insall JN, Scott WN, Scuderi GR, Font-Rodriguez D (1997) Total knee replacement in young, active patients. Long-term follow-up and functional outcome. *J Bone Joint Surg Am* 79:575–582
- Foruria X, Schmidt-Braekling T, Nabarte DA, Faschingbauer M, Kasperek M, Boettner F (2017) Does the tibia component design affect the need for offset stems in revision total knee arthroplasty? *Arch Orthop Trauma Surg* 137:853–860
- Insall JN, Dorr LD, Scott RD, Scott WN (1989) Rationale of the Knee Society clinical rating system. *Clin Orthop Relat Res* 2018:13–14
- Kumar N, Yadav C, Raj R, Anand S (2014) How to interpret postoperative X-rays after total knee arthroplasty. *Orthop Surg* 6:179–186
- Long WJ, Bryce CD, Hollenbeak CS, Benner RW, Scott WN (2014) Total knee replacement in young, active patients: long-term follow-up and functional outcome: a concise follow-up of a previous report. *J Bone Joint Surg Am* 96:e159
- Mahoney OM, Kinsey T (2010) Overhang of the femoral component in total knee arthroplasty: risk factors and clinical consequences. *J Bone Joint Surg Am* 92:1115–1121
- Matziolis G, Hube R, Perka C, Matziolis D (2012) Increased flexion position of the femoral component reduces the flexion gap in total knee arthroplasty. *Knee Surg Sports Traumatol Arthrosc* 20:1092–1096
- Peersman G, Taeymans K, Jans C, Vuylsteke P, Fennema P, Heyse T (2016) Malrotation deformities of the lower extremity and implications on total knee arthroplasty: a narrative review. *Arch Orthop Trauma Surg* 136:1491–1498
- Seil R, Pape D (2011) Causes of failure and etiology of painful primary total knee arthroplasty. *Knee Surg Sports Traumatol Arthrosc* 19:1418–1432
- Tan TL, Kheir MM, Modi R, Chen CL, Shao H, Chen AF (2017) Midterm Survivorship and complications of total knee arthroplasty in patients with dwarfism. *J Arthroplasty* 32:3364–3367
- Thienpont E, Schwab PE, Cornu O, Bellemans J, Victor J (2017) Bone morphotypes of the varus and valgus knee. *Arch Orthop Trauma Surg* 137:393–400

Publisher's Note Springer Nature remains neutral with regard to jurisdictional claims in published maps and institutional affiliations.