



ORIGINAL ARTICLE

Effects of a single intravenous dose of zoledronic acid on bone healing following tooth extraction in ovariectomized rabbits

Esra Mavi ^{a,*}, Peyami Turgay Hocaoglu ^b^a Cumhuriyet University, Faculty of Dentistry, Department of Oral and Maxillofacial Surgery, Sivas, Turkey^b Lokman Hekim University, Faculty of Dentistry, Department of Oral and Maxillofacial Surgery, Ankara, Turkey

Received 18 August 2019; revised 25 March 2020; accepted 30 March 2020

KEYWORDS

Bisphosphonates;
Zoledronic acid;
Ovariectomy;
Tooth extraction

Abstract Objective: The present study is aimed to investigate the effects of administering a single intravenous dose of zoledronic acid (ZA) on bone healing following tooth extraction in ovariectomized rabbits.

Materials and methods: Female, New Zealand rabbits were randomly divided into three groups including Control, ovariectomy + saline (OVX) and ovariectomy + zoledronic acid group (ZOL). Bilateral ovariectomy was performed to the rabbits in OVX and ZOL groups under general anesthesia. Control group underwent sham surgery. Eight weeks later, mandibular right incisors of all animals were extracted under general anesthesia. Before the procedure, Control and OVX groups were given saline and 0.1 mg/kg ZA was administered to ZOL group intravenously. All animals were sacrificed after 12 weeks.

Results: The findings of histopathological and biochemical evaluations reflected insignificant differences among study groups in vascular endothelial growth factor (VEGF), increases in osteoclasts, ossification, vascularization and mononuclear cell infiltration measures ($p > 0.05$). In contrast, bone morphogenic protein 2 (BMP-2), tumor necrosis factor alpha (TNF- α) and organization of the extraction wound differed significantly between groups ($p < 0.05$)

Conclusion: The potential beneficial effects of ZA administration on the wound healing process following tooth extraction were demonstrated via serum TNF- α , BMP-2 and VEGF levels in an osteoporotic model in ovariectomized rabbits.

© 2020 The Authors. Production and hosting by Elsevier B.V. on behalf of King Saud University. This is an open access article under the CC BY-NC-ND license (<http://creativecommons.org/licenses/by-nc-nd/4.0/>).

* Corresponding author at: Cumhuriyet University, Faculty of Dentistry, Department of Oral and Maxillofacial Surgery, 58140 Sivas, Turkey.
E-mail address: ealtunsoy@cumhuriyet.edu.tr (E. Mavi).

Peer review under responsibility of King Saud University.



Production and hosting by Elsevier

<https://doi.org/10.1016/j.sdentj.2020.03.016>

1013-9052 © 2020 The Authors. Production and hosting by Elsevier B.V. on behalf of King Saud University.

This is an open access article under the CC BY-NC-ND license (<http://creativecommons.org/licenses/by-nc-nd/4.0/>).

Please cite this article in press as: Mavi, E., Hocaoglu, P.T. Effects of a single intravenous dose of zoledronic acid on bone healing following tooth extraction in ovariectomized rabbits. Saudi Dental Journal (2020), <https://doi.org/10.1016/j.sdentj.2020.03.016>

1. Introduction

Osteoporosis is a skeletal disease characterized by an imbalance between bone resorption and formation, low bone mass and microarchitectural deterioration of bone tissue, with a consequent increase in bone fragility and susceptibility to fracture. It is a common metabolic disorder that affects postmenopausal women as a result of a decline in estrogen levels due to loss of ovarian function and postmenopausal osteoporosis mainly occurs in women over the age of 50 (Kroger et al., 1994). Distinctive characteristics and exact mechanism of the disorder have not been fully elucidated despite extensive clinical and preclinical studies.

Several studies have reported that bone loss associated with osteoporosis affects the jaws (Gilles et al., 1997). Delayed healing of extraction sockets was reported in rats with osteoporosis (Pereira et al., 2007). There are studies that displayed ovariectomy affects healing of dental socket after tooth extraction and impaired wound healing following tooth extraction by reducing new bone formation in rats (Shimizu et al., 2000).

Bisphosphonates (BPs) are known to inhibit bone resorption mediated by osteoclasts (Hu et al., 2002). BPs are pyrophosphate analogues. The core structure of BP molecules consists of a phosphate-carbon-phosphate chain which maintains its stability even after exposure to chemical and enzymatic hydrolysis. BPs increase in bone mineral density can reduce the risk of fracture (Otto et al., 2012). Although BPs inhibits osteoblastic activity minimally, they effectively prevent bone resorption mediated by osteoclasts (Fleisch, 1996). Similarly, some reports have suggested that the beneficial effects of BPs on bone mass and integrity may be mediated by their proliferative action on osteoblasts (Fromigue and Body, 2002). Thus, BPs may promote better and more rapid healing of tooth extraction sockets. Indeed, alendronate was reported to resist the loss of alveolar bone adjacent to extraction sockets (Altundal and Guvener, 2004).

BPs have been used for more than 40 years in the treatment of conditions associated with increased bone resorption including osteoporosis, primary and secondary hyperparathyroidism, hypercalcemia, Paget's disease of bone and osteolytic bone metastases and several other disorders (Rodan and Fleisch, 1996). However, they are strongly associated with different adverse drug reactions (ADR). Among these, osteonecrosis of the jaw (ONJ) is a serious side effect of BPs. It was initially described in 2003 by Marx; pamidronate (Aredia) and zoledronate (Zometa) induced avascular necrosis of the jaws: a growing epidemic (Marx, 2003).

It has been demonstrated that ZA was successful in preventing loss of bone mechanical strength and deterioration of bone structure in vertebrae and long bones in ovariectomized rats and in avoiding further bone loss in non-cancerous postmenopausal women (Hornby, 2003).

The aim of present study was to demonstrate favorable effects of systemic administration of ZA on wound healing following tooth extraction in an ovariectomized rabbit model.

2. Materials and method

The study protocol was independently reviewed and approved by the Institutional Review Board of Cumhuriyet University and the Committee for Ethical Treatment of Experimental Animals (date and number, 03.03.2014-24).

2.1. Animal subjects

For this study, 24 female New Zealand rabbits of 6 months of age with an average body weight of 2.5–3 kg were obtained from the Laboratory for Experimental Animals of Cumhuriyet University. Prior to initiation of the experiments, animals were accustomed to study conditions for 2 weeks. Experimental animals were placed in separate cages and kept at identical room temperature (22–24 °C), humidity (55–70%), and pressure (1 atm) conditions in 12 h/12 h light/dark cycles. Rabbits were given ad libitum access to standard diet pellets and water.

The animals were randomly divided into three groups (8 rabbits per group): sham-operated control group (Control) (Fig. 1A), ovariectomy + saline group (OVX) (Fig. 1B) and ovariectomy + ZA group (ZOL) (Fig. 1C).

2.2. Surgical technique

The abdominal regions of all rabbits were shaved and cleaned with a disinfectant (Poviodeks Batikon, Kimpa). Under aseptic conditions, all animals were given single doses of 10–20 mg/kg Xylazine (Rompun, Bayer, Istanbul, Turkey) and 50 mg/kg Ketamine HCl (Ketalar, Eczacıbaşı-Warner Lambert, Istanbul, Turkey) via intraperitoneal injection under general anesthesia prior to ovariectomy procedure.

Both ovaries were removed with bilateral incision and the surgical site was closed with 2.0 silk suture for OVX and ZOL groups and control group underwent sham surgery in which ovaries were examined and returned to their original position. The ovariectomy procedure was carried out in order to produce estrogen deficiency by simulating postmenopausal

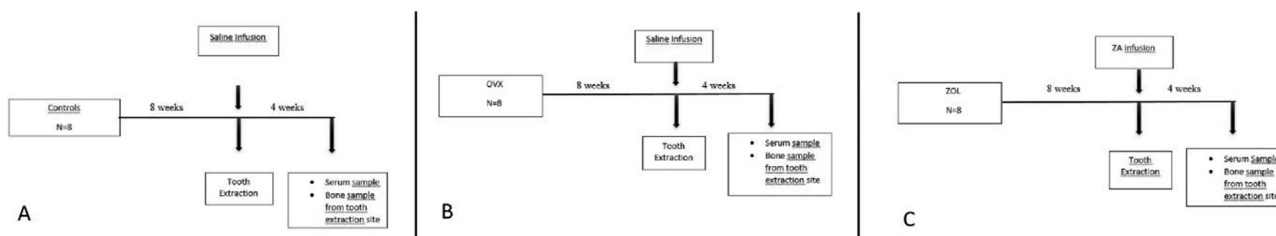


Fig. 1 A) Schematic representation of sham-operated control group (Control), B) Schematic representation of ovariectomy + saline group (OVX), C) Schematic representation of ovariectomy + Zoledronic acid group (ZOL).

state and the sham surgical operation was performed with the aim of exposing ovariectomized and non-ovariectomized rabbits to equal stress conditions (Fig. 2A,B).

2.3. Tooth extraction

Eight weeks after the ovariectomy operation, the oral region of all rabbits was cleaned with a disinfectant (Poviodeks Batikon, Kimpa). General anesthesia was performed on the animals via intraperitoneal injection of 10–20 mg/kg Xylazine (Rompun, Bayer, Istanbul, Turkey) and 50 mg/kg Ketamine HCl (Ketalar, Eczacıbaşı, Warner Lambert, Istanbul, Turkey). In all groups, right mandibular incisors were luxated with a bein elevator and extracted by a high-precision surgical technique using a mandibular incisor forceps (Fig. 2C,D,E). The teeth extraction sockets were closed with a vicryl suture (Ethicon 3.0, Johnson and Johnson, Sao Paulo, SP, Brazil). Prior to tooth extraction, saline infusions were administered to control and OVX groups and 0.1 mg/kg ZA (Zoledrin, Deva Holding A.Ş.) was administered to ZOL group by infusion via the ear vein.

2.4. Postoperative care of study animals and termination of the experiment

Prior to ovariectomy and tooth extraction procedures, 50 mg/kg Ceftriaxone (Cephaxon-Toprak) and 4 mg/kg Carprofen (Rimadyl-Phizer) were administered intramuscularly for pro-

phylaxis and then postoperatively for 3 days in order to prevent infection and provide analgesia. Four weeks after the operation, all animals were sacrificed using 200 mg/kg sodium pentobarbital (Petotal, Abbot, USA). Mandibles and surrounding soft tissues were removed in all animals via dissection and stored in 10% formalin solution for histopathological examination. Before sacrificing the animals, blood samples were collected into heparin tubes and centrifuged in a centrifuge device (NF 1200R centrifuge) for examination by ELISA assay.

2.5. Assessment methodology

2.5.1. Histopathological method

Extraction socket blocks were removed from rabbit mandibles and fixated in a 10% formalin solution. Following fixation, soft tissues were removed and bone tissues were decalcified in 1% nitric acid. Subsequent to decalcification, the tissues underwent routine tissue follow-up procedures and embedded in paraffin blocks in a tissue blocking device. 5- μ m sections were prepared, stained with hematoxylin, eosin and Von Kossa stains and then used for measurements of bone histomorphometric parameters. The tissue sections were examined under a light microscope (Leica DM 2500) and bone healing was evaluated by levels of osteoclast, ossification, vascularization, MNC infiltration, necrosis and organization of extraction wound.

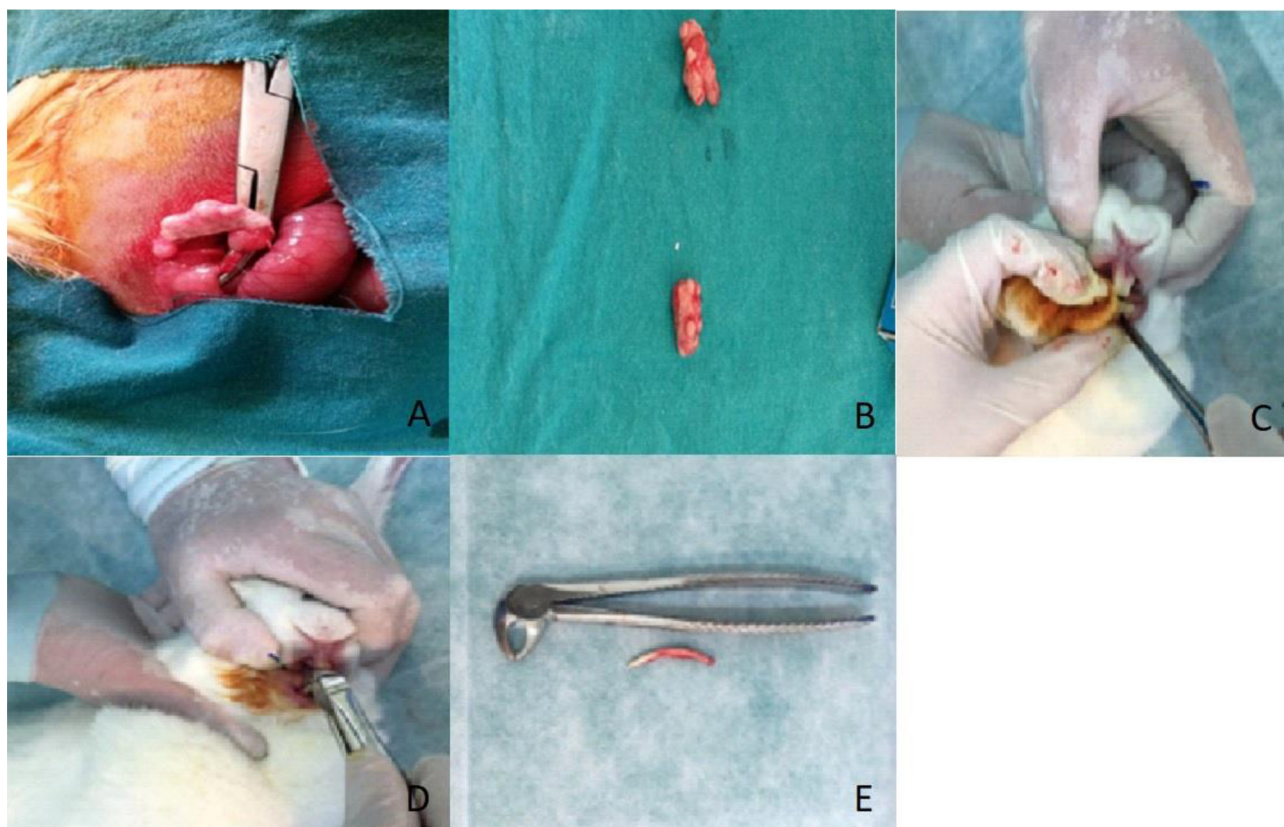


Fig. 2 A) Ovarian of rabbit, B) Excised rabbit ovaries C) Luxation of rabbit mandibular incisor tooth, D) Extraction of rabbit mandibular incisor tooth, E) The rabbit mandibular incisor tooth.

2.5.2. Biochemical method (ELISA)

ELISA analyses were performed according to written protocols. Blood samples were allowed to coagulate at room temperature for 10–20 min and then centrifuged for about 20 min at 2000–3000 RPM. Supernatants were carefully collected. When precipitates were formed during the procedure, centrifugation was repeated in the same manner. Collected serum samples were stored at -20°C until the time of analysis.

The samples, reagents and standards were prepared according to the established procedure (Table 1). Standard solutions and streptavidin-HRP were added into the standard wells and serum, BMP-2/TNF- α /VEGF antibodies and streptavidin-HRP were added into the sample wells. Microplates were incubated for 60 min at 37°C and rinsed five times. Chromogen reagents A and B were added and incubated for 10 min at 37°C . The color change was visualized. The reaction was terminated using a stop solution. Values were read by an ELISA reader (ThermoMultiskan GO Microplate Spectrophotometer) at 450 nm within 10 min.

2.6. Statistical analyses

Study data was analyzed using SPSS (Version 22.0) software package. The analysis of variance and Tukey test were performed when parametric test assumptions were met (Kolmogorov-Smirnov). Furthermore, the Monte Carlo model was used to obtain assumptions for chi-square exact test for contingency tables and chi-square values were estimated. An error rate of 0.05 was adopted for the study.

3. Results

3.1. Clinical findings

Throughout the experimental study, it was observed that rabbits well tolerated the surgical procedure with an overall good health status without any unfavorable effects on their nutrition and development of postoperative infections.

3.2. Histopathological findings

A histological examination was performed with specialist assistance of the chair of the Department of Veterinary Pathology. Microscopic examination of the histological sections obtained from study groups focused on osteoclastic activity, vascularization, necrosis, ossification, MNC cell infiltration and orga-

nization of extraction wounds (Fig. 4A–D). Histopathologic evaluation was scored 0 = None, 1 = Low, 2 = Moderate, 3 = Intense. In addition, the organization of the wound was evaluated and scored 0 = insufficient 1 = moderate, 2 = well.

When osteoclastic activity, vascularization, necrosis, ossification, MNC cell infiltration scores between groups were compared, differences between groups were statistically insignificant ($p > 0.05$). A significant difference was observed only between scores of organization of extraction wounds in groups ($p < 0.05$) (Fig. 3A–F).

3.3. Biochemical findings (ELISA Results)

Bone healing was assessed biochemically based on quantitation of BMP-2, VEGF and TNF- α .

BMP-2 measurements were found to significantly differ among study groups ($p < 0.05$). Pairwise comparison of BMP-2 values among groups showed a significant difference between the control group and ZOL ($p < 0.05$) with no significant difference between other groups ($p > 0.05$) (Table 2).

A significant difference was found between groups with respect to TNF- α measurements ($p < 0.05$). Pairwise comparison of TNF- α among groups demonstrated a significant difference between the control group and ZOL ($p < 0.05$) without any significant differences between other groups ($p > 0.05$) (Table 2).

VEGF values of study groups did not differ significantly ($p > 0.05$) (Table 2).

4. Discussion

Osteoporosis is an osteometabolic disease characterized by progressive bone resorption coupled with reduced osteogenesis (Nasu et al., 1998). Osteoporosis was experimentally induced by several methods in animals. Ovariectomy is the most common method to produce postmenopausal osteoporosis in animal models and thus, it was chosen for the present study (Devlin and Ferguson, 1990). Unlike other mammals, rabbits reach skeletal maturity rapidly after completing their full sexual development. The advantages of using rabbits in experiments are related to their accelerated bone turnover and shorter time frame to complete development in comparison to larger mammals like primates (Gilsanz et al., 1988).

The effects of osteoporosis on the jaw bones has been first documented in 1960 (Groen et al., 1960). There are studies reporting lower jaw bone density in ovariectomized rats compared to non-ovariectomized control rats. In one study, Cao et al. (2001) showed loss of mineralized bone in rabbit mandible 4 weeks after ovariectomy which was substantial 12 weeks after ovariectomy which mainly occurred in the trabecular bone area. Additionally, Meyer et al. (2001) explored the impact of estrogen deficiency on fracture healing in rats after ovariectomy and reported delayed fracture callus healing and poor mature bone formation. Also, Arslan et al. (2003) conducted a study to investigate the effects of estrogen deficiency-related osteoporosis on distraction osteogenesis in the tibial bones of 12 ovariectomized rabbits and showed inadequate formation of mature bone and delayed callus healing in the ovariectomized group.

BPs are the most commonly used agents for treatment of osteoporosis. They have a strong affinity to mineralized bone

Table 1 Procedure for preparation of the samples, reagents and standards.

800 ng/L	Standard no.5	120 μl original standard + 120 μl standard diluents
400 ng/L	Standard no.4	120 μl Standard no.5 + 120 μl standard diluents
200 ng/L	Standard no.3	120 μl Standard no.4 + 120 μl standard diluents
100 ng/L	Standard no.2	120 μl Standard no.3 + 120 μl standard diluents
50 ng/L	Standard no.1	120 μl Standard no.2 + 120 μl standard diluents

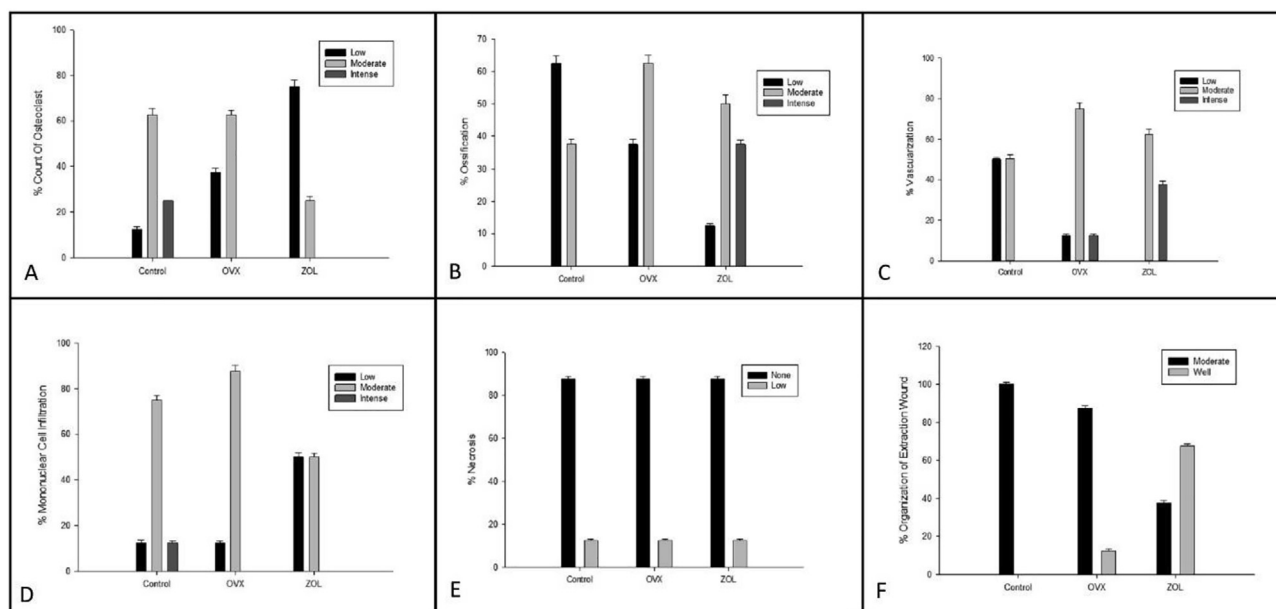


Fig. 3 Comparison of the amounts of osteoclastic activity (A), ossification (B), vascularization (C), mononuclear cell infiltration (D), necrosis (E) and organization of extraction wound (F) in all groups.

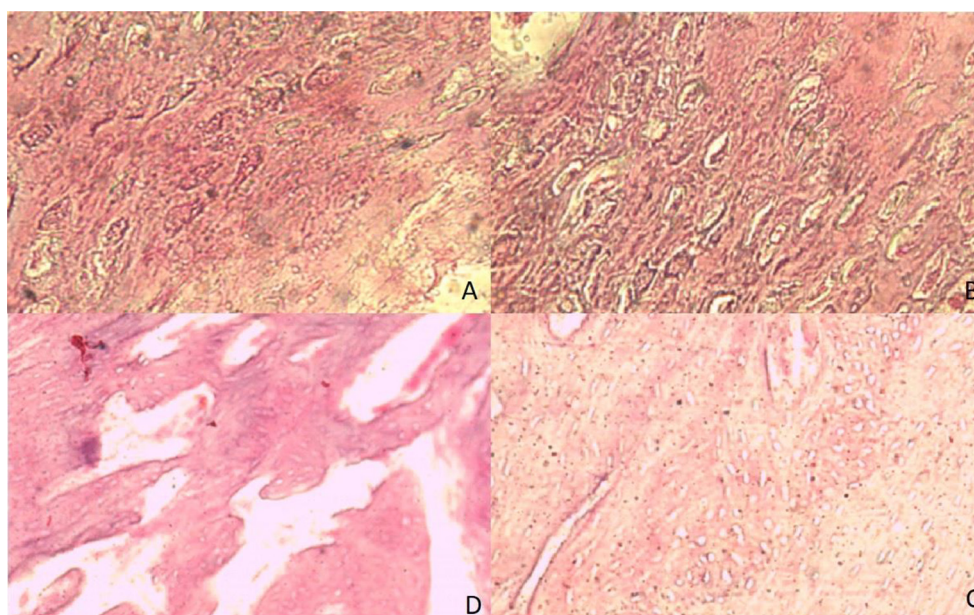


Fig. 4 A) Histopathological view of a section from the ovariectomy + Zoledronic acid group (ZOL) showing osteoclasts, Hematoxylin-Eosin $\times 260$, B) Histopathological view of a section from the ovariectomy + saline group (OVX) showing increased osteoclasts, Hematoxylin-Eosin $\times 260$, C) Histopathological view of a section from the ovariectomy + Zoledronic acid group (ZOL) showing intense ossification, Hematoxylin-Eosin $\times 120$, D) Histopathological view of a section from the ovariectomy + saline group (OVX) showing moderate ossification. Hematoxylin-Eosin $\times 180$.

and thus, they exert their actions mainly by inhibiting osteoclast-mediated bone resorption and normalizing high bone turnover rate (Gao et al., 2009). BPs inhibit osteoclastic activity and also inhibit differentiation of osteoclasts during prolonged use (Hughes et al., 1989). BPs are synthetic analogues of inorganic pyrophosphates and have a strong affinity to calcium. BPs are metabolized rapidly in blood cycle, easily

linked to bone minerals and accumulated within bones selectively (Fleisch, 2000).

Estrogen deficiency was reported to result in reduced alveolar bone density which can be prevented by alendronate (Altundal and Guvener, 2004). Sener et al. (2009) reported that alendronate led to decreases in plasma and urinary calcium levels after tooth extraction in rats and concluded that alen-

Table 2 Comparison of levels of bone morphogenetic protein-2 (BMP2), tumor necrosis factor α (TNF- α) and vascular endothelial growth factor (VEGF) between the groups.

Groups	BMP2 $x \pm Ss$	TNF- α $x \pm Ss$	VEGF $x \pm Ss$
Control	171,25 \pm 9,36	60,90 \pm 3,84	485,46 \pm 51,01
OVX	195,77 \pm 23,37	69,75 \pm 11,12	515,20 \pm 44,14
ZOL	201,06 \pm 29,75	78,19 \pm 8,02	529,16 \pm 40,77
Results	F = 3,99	F = 8,46	F = 1,92
	p = 0,034*	p = 0,002*	p = 0,171*

dronate could be safely used to prevent bone resorption. In the current study, estrogen deficiency was induced by ovariectomy and the impact of intravenous administration of ZA on wound healing after tooth extraction was evaluated.

ZA is an amino-bisphosphonate used intravenously and the most potent drug in this pharmacological class (Dodson, 2009). While ZA can be administered via intraperitoneal and subcutaneous injections, IV injection is the most common technique. Taking into account the reports that showed local tissue injury and irritation associated with subcutaneous injection method and the fact that BPs are poorly absorbed from the gastrointestinal system, 0.1 mg/kg ZA was given intravenously in the present study. In preclinical animal experiments, various doses of ZA were tested for subcutaneous and intravenous administrations. The most commonly preferred dose of ZA has been 0.1 mg/kg. The amount of this dose is based on the equivalence of animal dose of 0.1 mg/kg with human clinical dose of 0.067 mg/kg. This corresponds to a human dose of approximately 4.5 mg for an adult individual weighing 65 kg (Gasser et al., 2006). Thus, 0.1 mg/kg dose used for animal experiments is the dose that closely matches the therapeutic dose that would be used in humans. In light of these data, 0.1 mg/kg dose of ZA was administered to study animals via intravenous route.

In a study by Tatli et al. (2011) showed that administration of ZA improved early wound healing and resistance to mandibular fracture in rats. They reported that a single systemic dose of zoledronic acid accelerated and promoted fracture healing in the maxillofacial region. Several years ago, Lespessailles et al. (2009) found that a single 20 μ g/kg dose of intravenous zoledronic acid provided comparable increase in the trabecular bone mass in ovariectomized rat tibia versus the healthy control group. Dikicier et al. (2014) examined the effects of systemic administration of zoledronic acid on implant osseointegration in their ovariectomized rat model. They reported that zoledronic acid significantly increased implant-bone contact as a result of histomorphometric analysis. Sener et al. (2013) studied the effect of zoledronic acid on mandibular fracture healing in an osteoporotic animal model. They reported an increase in new bone formation in the zoledronic acid group but the difference was not statistically significant compared to the control group. Pampu et al. (2008) examined the effect of zoledronic acid on distraction osteogenesis histomorphometrically. They reported that zoledronic acid had a positive effect on new bone formation and could shorten the consolidation period. Consistent with these findings, ZA-treated group had significantly better bone organization in the tooth extraction socket compared to other groups at 4 weeks after tooth extraction in our study.

Biological markers are used in medicine to determine the nature and activity of the inflammation as well as for monitoring the response to treatment. As reported previously by several investigators, TNF- α which indicates immune response elicited at the time of inflammatory changes in the tissues may be used to determine the resulting inflammatory state. In the present study, TNF- α levels were found to differ significantly among study groups ($p < 0.05$). Pairwise comparisons of values of study groups showed a significant difference between controls and ZOL ($p < 0.05$) with non-significant changes between other groups ($p > 0.05$). These findings may be interpreted to indicate favorable effects of ZA which resulted in reduced severity and duration of inflammation when administered after tooth extraction. This interpretation which is based on TNF- α measurements is also consistent with histopathological findings of the study such that 50% of the ZOL subjects had a low mononuclear cell infiltration score and 87.5% of the OVX subjects had a moderate mononuclear cell infiltration score. Intense mononuclear cell infiltration score was only found in the control group.

Similarly, it was shown that BMPs led to migration and transformation of undifferentiated mesenchymal cells into osteoblasts following activation through chemotaxis, storage of bone matrix, mineralization of newly stored bone matrix and bone marrow differentiation when they were implanted with an appropriate transporter (Ripamonti and Duneas, 1998). Some studies have shown that owing to these capabilities, BMPs may be used to monitor bone damage and healing. In light of literature data, current study findings of statistically significant differences between groups in BMP-2 levels ($p < 0.05$) and a significant difference between controls and ZOL in BMP-2 levels in pairwise comparisons ($p < 0.05$) may indicate contribution of ZA to new bone formation in tooth extraction sockets. Additionally, when ossification scores from histopathological examinations were compared, ossification was scored as low in 62.5% of the control subjects and a moderate score of ossification was observed in 62.5% of the OVX subjects. Ossification was scored as intense in only 37.5% of the ZOL subjects. These results coincide with BMP2 levels measured in the study and lend support to our hypothesis that ZA contributes to wound healing following tooth extraction.

As shown by previous studies, VEGF is released by endothelial cells, chondrocytes, platelets, megakaryocytes, lymphocytes and plasma cells and their target cells are osteoblasts and endothelial cells. Their biological functions include angiogenesis, neovascularization, and growth and repair of cartilage and bones (Banks et al., 1998). In the current study, VEGF values were not statistically significantly different among study groups ($p > 0.05$). This serologic finding is consistent with vascularization scores as demonstrated microscopically.

5. Conclusion

In the present study, favorable effects of ZA on wound healing process after tooth extraction were shown in a rabbit osteoporosis model following ovariectomy via serum TNF- α , BMP-2 and VEGF measurements. On histological examinations, ZA was found to reduce the severity of inflammation occurring in the tooth extraction wound and increase ossification.

ZA is 10-fold more potent than pamidronate. However, we believe that the risk of osteomyelitis was low since we administered a single low dose of ZA and other factors involved in the development of osteomyelitis were absent such as the blood supply to jaws was favorable. Further studies are needed to establish the safety of ZA treatment in the setting of tooth extraction.

Declaration of Competing Interest

The authors declare that they have no known competing financial interests or personal relationships that could have appeared to influence the work reported in this paper.

References

- Altundal, H., Guvener, O., 2004. The effect of alendronate on resorption of the alveolar bone following tooth extraction. *Int. J. Oral Maxillofac. Surg.* 33 (3), 286–293.
- Arslan, H. et al, 2003. The effects of osteoporosis on distraction osteogenesis: an experimental study in a rabbit model. *Acta Orthop. Belg.* 69, 67–73.
- Banks, R. et al, 1998. Release of the angiogenic cytokine VEGF from platelets; significance for VEGF measurements and cancer biology. *Br. J. Cancer* 77, 956–964.
- Cao, T. et al, 2001. Bone mineral density in mandibles of ovariectomized rabbits. *Clin. Oral Implants Res.* 12 (6), 604–608.
- Devlin, H., Ferguson, M.W.J., 1990. The rate of incisor dentine calcification and of mandibular growth in the molar region of the ovariectomized rat. *Arch. Oral Biol.* 35, 29–32.
- Dikicier, E. et al, 2014. Effect of systemic administered zoledronic acid on osseointegration of a titanium implant in ovariectomized rats. *J. Cranio-Maxillofacial Surg.* 42 (7), 1106–1111.
- Dodson, T.B., 2009. Intravenous bisphosphonate therapy and bisphosphonate-related osteonecrosis of the jaws. *J. Oral Maxillofac. Surg.* 67, 44–52.
- Fleisch, H., 1996. The bisphosphonate ibandronate, given daily as well as discontinuously, decreases bone resorption and increases calcium retention as assessed by ⁴⁵C kinetics in the intact rat. *Osteoporos. Int.* 6, 166–170.
- Fleisch, H., 2000. *Bisphosphonates in Bone Disease: From the Laboratory to the Patients.* Academic Press, San Diego.
- Fromigue, O., Body, J.J., 2002. Bisphosphonates influence the proliferation and the maturation of normal human osteoblasts. *J. Endocrinol. Invest.* 25, 539–546.
- Gao, Y. et al, 2009. Effect of combined local treatment with zoledronic acid and basic fibroblast growth factor on implant fixation in ovariectomized rats. *Bone* 44 (2), 225–232.
- Gasser, J.A. et al, 2006. A single intravenous administration of zoledronic acid prevents the bone loss and mechanical compromise induced by aromatase inhibition in rats. *Bone* 39, 787–795.
- Gilles, J.A. et al, 1997. Oral bone loss is increased in ovariectomized rats. *J. Endod.* 23, 419–422.
- Gilsanz, V. et al, 1988. Effect of sex steroids on peak bone density of growing rabbits. *Am. J. Physiol.* 255 (18), 416–421.
- Groen, J.J. et al, 1960. Diffuse alveolar atrophy of the jaw (non-inflammatory form of paradental disease) and pre-senile osteoporosis. *Gerontol. Clin.* 2, 68–86.
- Hornby, S.B., 2003. Long-term zoledronic acid treatment increases bone structure and mechanical strength of long bones of ovariectomized adult rats. *Calcified Tissue Int.* 72 (4), 519–527.
- Hughes, D.E. et al, 1989. Inhibition of osteoclast-like cell formation by bisphosphonates in long-term cultures of human bone marrow. *J. Clin. Invest.* 83, 1930–1935.
- Hu, J.H. et al, 2002. Effects of short-term alendronate treatment on the three-dimensional microstructural, physical, and mechanical properties of dog trabecular bone. *Bone* 31 (5), 591–597.
- Kroger, H. et al, 1994. Bone mineral density and risk factors for osteoporosis population-based study of 1600. *Calcif. Tissue Int.* 55 (1), 1–7.
- Lespessailles, E. et al, 2009. Does exercise modify the effects of zoledronic acid on bone mass, microarchitecture, biomechanics, and turnover in ovariectomized rats?. *Calcif. Tissue Int.* 85, 146–157.
- Marx, R.E., 2003. Pamidronate (Aredia) and zoledronate (Zometa) induced avascular necrosis of the jaws: a growing epidemic. *J. Oral Maxillofac. Surg.* 61, 1115–1117.
- Meyer Jr, R.A. et al, 2001. Age and ovariectomy impair both the normalization of mechanical properties and the accretion of mineral by the fracture callus in rats. *J. Orthop. Res.* 19, 428–435.
- Nasu, M. et al, 1998. Osseointegration in implant-embedded mandible in rats fed calcium-deficient diet: a radiological study. *Oral Dis.* 4, 84–89.
- Otto, S. et al, 2012. Bisphosphonate-related osteonecrosis of the jaws - characteristics, risk factors, clinical features, and impact on oncological treatment. *J. Craniomaxillofac. Surg.* 40, 303–309.
- Pampu, A.A. et al, 2008. Histomorphometric evaluation of the effects of zoledronic acid on mandibular distraction osteogenesis in rabbits. *J. Oral Maxillofac. Surg.* 66 (5), 905–910.
- Pereira, M.C. et al, 2007. Ovariectomy delays alveolar wound healing after molar extractions in rats. *J. Oral Maxillofac. Surg.* 65 (11), 2248–2253.
- Ripamonti, U., Duneas, N., 1998. Tissue Morphogenesis and regeneration by morphogenetic proteins. *Plast. Reconstr. Surg.* 101, 227.
- Rodan, G.A., Fleisch, H.A., 1996. Bisphosphonates: mechanisms of action. *J. Clin. Invest.* 97, 2692–2696.
- Sener, A. et al, 2009. The effect of alendronate on plasma biochemical parameters and oxidative stress following tooth extraction in rats. *GÜ Diş Hek Fak Derg.* 26 (3), 147–153.
- Sener, I. et al, 2013. The effects of zoledronic acid on mandibular fracture healing in an osteoporotic model: a stereological study. *J. Craniofac. Surg.* 24 (4), 1221–1224.
- Shimizu, M. et al, 2000. Bone wound healing after maxillary molar extraction in ovariectomized aged rats: quantitative backscattered electron image analysis. *Anat. Rec.* 259 (1), 76–85.
- Tatli, U. et al, 2011. Effects of zoledronic acid on healing mandibular fractures: An experimental study in rabbits. *J. Oral Maxillofac. Surg.* 69, 1726.